

# Explaining Laminitis and its Prevention

©

Robert A Eustace BVSc Cert EO Cert EP FRCVS

The Laminitis Clinic, Mead House, Dauntsey, Chippenham, Wilts. SN15 4JA. England

## Chapter 2 - What happens within the foot during laminitis ?

It seems that the basic problem in laminitis is an interruption to the normal blood flow to the laminar corium early in the development of laminitis ( possibly causing activation of matrix metalloproteinase enzymes which shed the epidermal cells from the basement membrane). Areas of laminar corium are deprived of their normal blood supply by two mechanisms a) the arteries and veins clamp down constricting the diameter of the blood vessels; and b) blood is shunted away from the tissues of the laminar corium directly into the veins. This shunting occurs via specialised vessels called arteriovenous anastomoses opening and allowing blood from the high pressure arterial side of the circulation to flow directly into the veins without flowing through the laminar corium. This loss of normal blood supply is known as ischaemia (iskeemear). We know that it takes about four minutes for areas of the human brain to be irreparably damaged by lack of blood supply when a person has a stroke; this is the same type of damage which occurs in the laminae of a horse's foot during the early stages of laminitis. The severity of damage to the laminar corium is determined by a) the time during which ischaemia persists, and b) the area of the laminar corium which is affected.

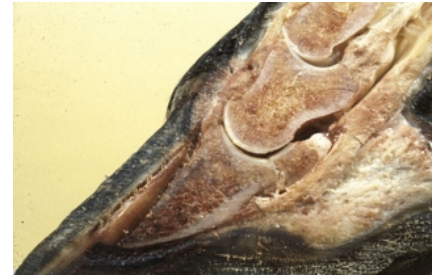

Figure 14. Split foot of a case of acute founder (compare with Fig. 25).

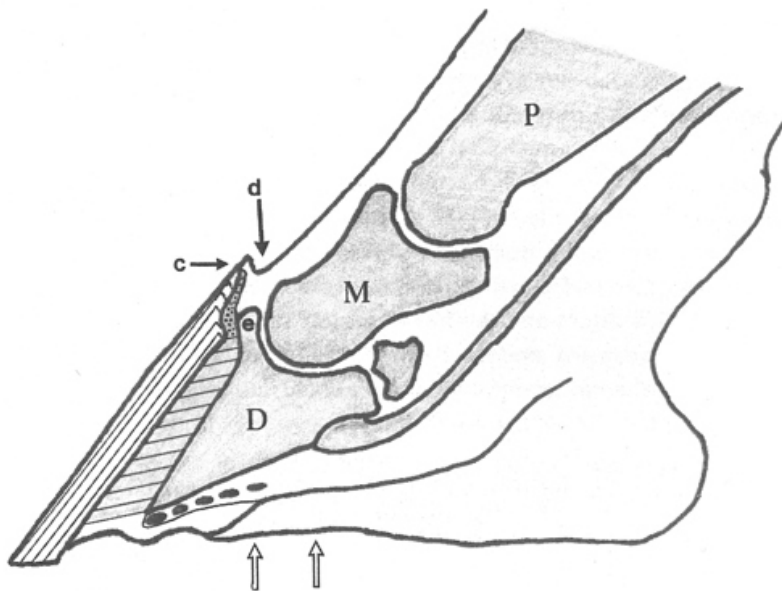


Figure 15. Diagrammatic representation of the acute founder foot in Figure 14. Stippled area = coronary corium; hatching = stretched dermal and epidermal laminae, becoming separated by leakage of fluid from blood vessels in the laminar corium; black dots = compressed circumflex artery and blood vessels in the solar corium. Note how the phalangeal bones (P, M & D) are no longer aligned. There is an increased vertical distance between the extensor process (e) and the coronary band (c), this has resulted in a squashing of the coronary corium. The downward movement of the pedal bone has created a depression at the coronary band (d) which is characteristic of acute founder and which can be felt with the fingers. The front of the pedal bone and the front of the hoof wall are no longer parallel, the space in between has filled up with serum and blood which has forced the two structures apart. The circumflex artery of the pedal bone and the blood vessels in the solar corium have become squeezed between the descending pedal bone and the horny sole which is no longer concave. Support to the pedal bone can only be provided by fitting a frog support or heart bar on the part of the frog between the two open arrows.

If the blood supply is interrupted for a short time no permanent damage is likely to be done. The more severe the reduction in supply and the longer this reduction continues the greater the likelihood of irreversible changes in the laminar corium. If the blood vessels remain constricted for very long, a matter of hours, the internal lining may become damaged. Following this damage the cells lining the blood capillaries swell and tend to separate causing gaps in the blood vessel walls. Fluid from the blood then leaks out through these gaps, further increasing the already high fluid pressure in the foot. Secondly there is a tendency for blood clots to form by sticking to the damaged cells lining the capillaries. A vessel that becomes full of blood clot is permanently occluded.

Why does this lack of blood supply cause such pain in laminitis? Any interruption to blood flow in this situation is painful as the laminar tissue becomes starved of oxygen and nutrients. There is evidence that further pain can occur when the blood supply is restored, this is called a reperfusion injury. Laminitis results from lack of blood flow to the laminar corium, it is not at this stage an inflammatory disease at all. If the blood supply is normalised fairly quickly the animal recovers with no after effects.

However if the reduction in blood supply is severe, long standing, or affects most of the laminar corium then the attachment between the pedal bone and the hoof capsule will start to fail. This occurs directly from a mechanical point of view as there is an insufficient area of healthy laminar corium left to support the pedal bone. When this situation is reached the animal is said to start to FOUNDER.

# Explaining Laminitis and its Prevention



Robert A Eustace BVSc Cert EO Cert EP FRCVS

The Laminitis Clinic, Mead House, Dauntsey, Chippenham, Wilts. SN15 4JA. England

We have seen that because of the anatomy of the blood supply it is the laminar corium in the front of the foot which is the most easily starved of blood. In acute founder cases, i.e. those which have occurred suddenly and recently, it is the laminar corium in this front area which is the more severely affected. As the support to the pedal bone is weakened, the initial movement of the pedal bone is downwards and backwards as the weight of the horse above overcomes the support by the damaged interlocking laminae (Fig. 14). Before the dermal and epidermal laminae are actually pulled apart they become stretched. If the foot is X-rayed at this stage this can be diagnosed by an increase in the distance between the front of the wall and the front of the pedal bone; this is called an increase in wall thickness. By comparing Figures 13 and 15 it can be seen that several important changes have occurred in the foundered foot. The phalangeal axis is not quite in a straight line and the front of the pedal bone is no longer parallel to the front of the hoof capsule. The angulation between these two structures has been referred to as the angle of 'rotation' of the pedal bone. We shall see later that this angle of rotation, so often quoted, is not the only angle of rotation. In the acute founder case the separation between the bone and hoof capsule is due to the escape of fluid from the damaged laminar vessels into the spaces created by the inter-digitating laminae being pulled apart. The fluid causing this separation is blood and serum (the fluid part of the blood without the cells).

The coronary corium is no longer oval in cross-section but has become compressed due to pinching between the top of the hoof wall and the front of the coffin joint. The coronary papillae are no longer aligned parallel to the front of the pedal bone. They are very bent due to the downward pull of the attached pedal bone (Fig. 16). Unless these coronary papillae can heal and re-orientate, the horse will never have a normal foot again. Due to the downward movement of the pedal bone, the circumflex artery and the blood vessels of the solar corium become pinched between the underside of the pedal bone and the horny sole. This cuts off the blood supply to the solar corium and may rupture some of the vessels in the solar corium particularly around the 'tip' of the pedal bone. If the founder gets no worse, these cases can be recognised about six weeks later by a blood stained area in the horn of the sole. This area is always crescent shaped, corresponding to the shape of the pedal bone, and is about mid way between the toe and the point of frog. Additionally, the blood vessels within the laminar and coronary corium over the front of the pedal bone become stretched and often rupture during acute founder. This releases blood into the surrounding horn. In white footed animals blood from the coronary corium can be seen on the wall as a red ring which grows down the foot. Blood from ruptured vessels in the laminar corium is on the inner side of the hoof wall and tends to be seen at the white line of the toe some months later.



Figure 16. View of the coronary papillae in the midline from a case of acute founder. Notice how the papillae and the juvenile horn tubules have become bent by the downward movement of the pedal bone. Compare to the normal situation in Figure 7.

If the founder worsens and the pedal bone keeps descending, the horny sole becomes flattened or even convex. Thus in the acutely foundered horse, in addition to the reduction in blood supply due to laminitis, the situation is worse because the descending pedal bone has physically distorted the blood vessels. The circumflex artery of the distal phalanx and the vessels of the solar corium have become trapped between the pedal bone and the horny sole (Fig. 15). In severe cases the bone may push right through the horny sole; this is known as solar prolapse (Fig. 56). It can be appreciated that the further the pedal bone moves down, the worse the degree of founder. It is possible to tell whether a horse is foundered by feeling around his coronary bands. In the normal horse, if you run your finger down the front of the pastern, over the coronary band and onto the hoof wall, your finger slides easily. If the horse is foundered your finger tends to lodge in a ditch or depression just above the coronet. When the horse founders and the pedal bone moves down, it drags the tissues under the skin with it which creates the ditch you can feel with your finger (Fig. 15). The deeper the ditch and the farther it extends sideways around the coronet, the worse the founder (Fig. 17).

There is a special sort of founder; and it is the most serious. In some cases the blood supply to the whole of the laminar corium, right back to the heels, has been savagely starved of blood supply. In these cases the pedal bone becomes detached from the hoof capsule all the way round the foot as all the laminar corium is affected. The pedal bone is loose within the hoof; these cases are known as SINKERS (Fig 18) . The coronary papillae are bent, not just in the front part of the foot but right back to the heels. The pedal bone is no longer suspended by the laminae but is resting on the inside of the horny sole thus cutting off the blood flow to the solar and laminar corium. In these cases the ditch extends all the way around the coronet from one heel to the other. There is only a matter of hours in which to attempt to save most of these cases. However, if the correct treatment is provided in time, within a few hours, they can be cured and return to working lives.



# Explaining Laminitis and its Prevention



Robert A Eustace BVSc Cert EO Cert EP FRCVS

The Laminitis Clinic, Mead House, Dauntsey, Chippenham, Wilts. SN15 4JA. England

## Healing

Laminitis cases, although they may be in acute pain temporarily, should respond to treatment and be left with no permanent changes in the feet. Founder cases will be left with some degree of foot distortion if corrective treatment is not provided. Even if treatment is provided some unresponsive cases will show a degree of hoof abnormality characteristic of CHRONIC FOUNDER. Chronic means 'of long standing' i.e. the opposite of acute. 'Chronic' infers nothing about the severity of the condition. These changes are directly attributable to the movement of the pedal bone within the hoof. The toe of the foot tends to elongate, the front wall may become curved and the heels of the foot grow more quickly than the toe (Fig. 19). Additionally, the coronary band appears less distinct than normal;

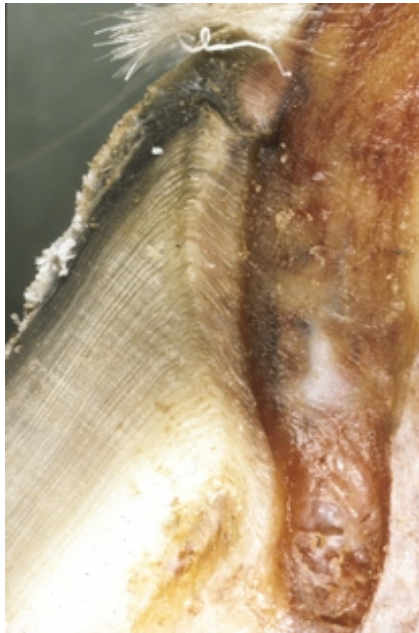


Figure 18. The coronary papillae and juvenile horn tubules are severely bent in this case of sinker syndrome. Compare to Figures 7 & 16. Although this tissue has been taken from the midline, in a sinker the same deformation would be shown by coronary papillae at the heels.

the hoof wall seems to merge with the skin. The white line of the foot becomes stretched or wider than normal around the toe of the foot. The sole of the foot may appear flat or dropped i.e. lower than the hoof wall at the ground surface. When the pedal bone moves down the coronary papillae may become permanently damaged leading to a reduced rate of growth compared with the unaffected part of the coronary corium at the heels. This can be seen easily if the animal has growth rings on the hoof walls. If a horse has foundered the rings will be wider at the heels than the toe. (It is important to differentiate between the growth rings of chronic founder and those of a change in diet. Chronic founder rings are divergent, i.e. wider at the heels than the toe whereas the rings caused by a change in feeding are the same width all the way round the foot.) When the two sets of laminae are pulled apart, the surface of the healing laminae may be altered leading to an abnormally high rate of production of laminar horn which grows straight forwards leading to the elongating toe and stretched white line. This alteration to the laminae is not always permanent. Flattening of the sole is due to the new, lower position of the pedal bone within the hoof. This flattening of the sole can be reversed in many cases by surgical treatment to the deep digital flexor tendon and heart bar shoeing.

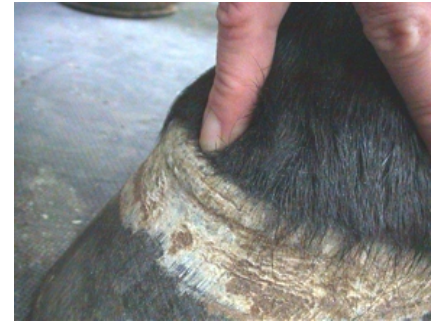

Figure 17. How to feel for the depression at the coronary band indicative of acute founder or sinker syndrome. Run the finger lightly down the pastern and over the coronary band onto the hoof wall. There is no resistance to this procedure in the normal animal: in a case of acute founder or sinker syndrome the finger tends to lodge in a depression as shown in the figure.

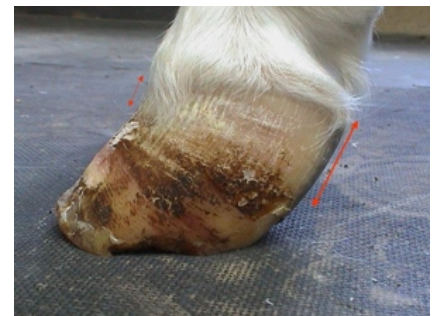

Figure 19. A foot showing the classical changes of chronic founder, high heels, concave front wall and divergent growth rings. Many of these types of case can be dramatically improved by correct foot trimming and shoeing.

From the foregoing, it is possible for you and your veterinary surgeon to tell the difference between a case of LAMINITIS, ACUTE FOUNDER, SINKING or CHRONIC FOUNDER just by looking at the feet. It is important that these different types of the basic condition are recognised as each carries a different prognosis and each can be expected to respond to treatments differently. Prognosis means the prediction of the outcome following treatment i.e. whether the animal will be cured or not. Treatment that consists of a balanced combination of medical, farriery and possibly surgical approaches has the best chance of success. The sooner correct treatment is started the better the chance of recovery. Prompt treatment is mandatory for the more severe forms, the acute founder and sinker cases. I will begin by describing the foot treatments that are recommended for each type of case.